

# Glans Ischemia After Circumcision

Anna Black,✉ Ryan Paterson

Department of Urologic Science, University of British Columbia, Vancouver, Canada

A 28-year-old otherwise healthy male underwent an uncomplicated circumcision under general anaesthetic supplemented with a ring and dorsal nerve block of the injected 15 mL of 0.25% plain bupivacaine. The skin and mucosal collars were reapproximated with simple 4-0 Vicryl Rapide sutures, and the penis was loosely wrapped with Vaseline gauze, and 2-inch Kling gauze. The patient was discharged uneventfully from the recovery room.

Approximately 6 hours after surgery, the patient returned to the emergency room as the exposed glans penis appeared black and felt firm. The penile dressings were immediately removed. Examination revealed a cool, black glans with an abrupt transition distal to where the dressings had been applied (Figure 1). The glans softened after dressing removal and the suture line was not restrictive. There was decreased sensation to the entire penis but no pain. The patient was voiding normally.

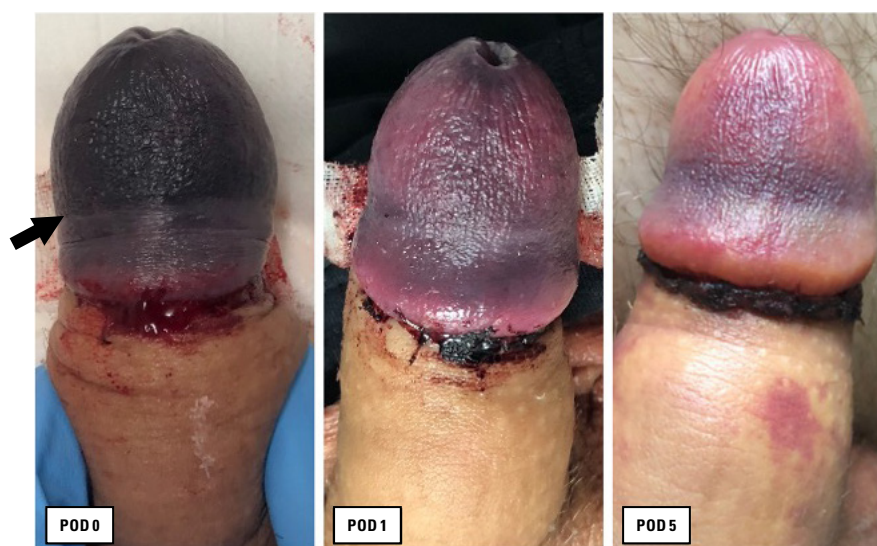
Our clinical impression was the unusual event of ischemia of the glans secondary to venous congestion from a tight dressing. With all dressings removed, the patient was admitted to hospital for observation with ancillary measures of one 50 mg dose of intravenous hydrocortisone as well as prophylactic cefazolin and commencement of aspirin 325 mg daily.

Upon reassessment the subsequent morning, the glans had re-perfused with patches of pink colouration interrupted by purple discolouration. Distal penile sensation had improved. The patient was discharged home on aspirin 325 mg and prophylactic cephalexin for 7 days.

On the 5th postoperative day the reperfusion continued to improve, and by the 12th day there were only a few scattered areas of purple discolouration. Four months postoperatively, the patient had made a full recovery with a good cosmetic result and no voiding or erectile dysfunction.

## FIGURE 1.

Discolouration and reperfusion of the glans penis after circumcision. Images of the glans are shown on postoperative day (POD) 0, 1, and 5. The arrow indicates the distal margin of the dressing that was applied after circumcision and removed upon admission to the ER.



## Key Words

Male circumcision, postoperative complications, ischemia

## Competing Interests

None declared.  
Patient Consent: Obtained.

## Article Information

Received on December 13, 2022  
Accepted on December 15, 2022  
Soc Int Urol J. 2023;4(3):231  
DOI: 10.48083/ECNT1039